

Headless self-compressing cannulated screw fixation for treatment of radial carpal bone fracture or fissure in dogs

K. Perry; N. Fitzpatrick; J. Johnson; R. Yeadon

Fitzpatrick Referrals, Eashing, Godalming, Surrey, UK

Keywords

Acutrak, radial carpal bone, scaphoid, compression screw, carpal arthroscopy

Summary

Objectives: To report the application and clinical outcome of the treatment of radial carpal bone fracture in five dogs using a variably-pitched, headless cannulated compression screw (Acutrak®).

Methods: Arthroscopy was performed prior to surgical repair in three cases. In two cases, a fissure within the radial carpal bone was more clearly apparent when oblique indirect illumination was employed at arthrotomy. Following Acutrak® screw placement via arthrotomy, external coaptation was applied in all cases for a period of two weeks.

Results: Five dogs were treated, of which four were Boxers, and one was a Labrador Retriever crossbreed. All dogs were lame prior to treatment. There was no history of trauma, and all dogs had soft tissue swelling on the dorsal aspect of the radiocarpal joint. In all cases the fissure or fracture line was oblique

in orientation, extending disto-medially from the midpoint of the radiocarpal joint proximally to the level of the second carpal bone distally. All fractures treated demonstrated progressive radiographic healing, and all dogs were free of lameness at six weeks post-operatively, but two of the five fractures failed to reach complete radiographic union. All dogs remained lameness-free with mean follow-up of 12.5 months.

Discussion: Acutrak® screws are headless devices which achieve compression, even in small bone fragments. Threads engage both the near and far fracture segments, leading to increased screw-bone contact which maximizes pull-out strength and may increase the fatigue strength of the screw.

Clinical significance: Fixation of two-piece canine radial carpal bone fractures with the Acutrak® screw proved a reliable alternative to conventional compression screw fixation, and may have benefits over alternatives attributable to screw design and application technique.

intermediate, central and radial. Fusion of these centres should occur between five and six months of age (2). Multiple studies have indicated a propensity for fractures of the radial carpal bone to occur along these lines of ossification and a breed predisposition has been noted in the Boxer (2–4). Certain fractures may develop without obvious trauma and it has been speculated that incomplete fusion of the three ossification centres of this bone may contribute to this (5). Radial carpal bone fractures have been classified into four main types, three of which involve fracture lines which extend to involve either the proximal or distal articular surfaces, or both. Oblique mid-body fractures, comminuted T-shaped fractures, dorsal margin chip fractures and palmar process fractures have all been reported, with oblique mid-body fractures being the most common in some studies (3, 5, 6). Histopathological samples taken from two dogs with radial carpal bone fracture demonstrated the presence of persistent cartilaginous areas within immature cancellous bone and fibro-connective tissue on the fracture surfaces (7). This was considered to be indicative of incomplete ossification rather than a true fracture of the radial carpal bone (7). These findings were similar to those reported in cases of incomplete ossification of the humeral condyle (8, 9).

The canine radial carpal bone corresponds to the fused scaphoid and lunate bones of the human wrist (10). Bipartite scaphoid and lunate bones in humans are well documented with an incidence of up to 0.5% (11–13). Scaphoid bone fractures make up 80% of all carpal fractures in humans and are classified as middle third (waist), proximal pole or distal third (14). Blood supply to the proximal pole of the scaphoid is solely reliant on intraosseous

Correspondence to:

Noel Fitzpatrick, MVB, CertSAO, CertVR
Fitzpatrick Referrals
Halfway Lane
Eashing, Godalming, Surrey GU7 2QQ
United Kingdom
Phone: + 44 1252 794900
Fax: + 44 1252 793477
E-mail: noelf@fitzpatrickreferrals.co.uk

Vet Comp Orthop Traumatol 2010; 23: 84–101

doi:10.3415/VCOT-09-01-0006

Received: January 15, 2009

Accepted: November 14, 2009

Pre-published online: February 11, 2010

Introduction

Fracture or fissure of the radial carpal bone is an uncommon cause of forelimb lameness in the dog (1, 2). The exact aetiology remains

unknown, however fatigue from cyclic overload and structural failure due to a pre-existing weakness have been proposed (3).

The radial carpal bone of dogs forms from three distinct centres of ossification:

circulation; therefore the scaphoid is prone to nonunion if the blood supply is damaged (14).

Various treatment options for the fractured human scaphoid bone have been documented, including conservative management, external coaptation and internal fixation using a variety of implants. A variety of grafting procedures have also been reported, including the use of iliac cancellous bone grafts, cortico-cancellous graft from the distal radius, cortical grafts and palmar-radial wedge grafts (15–18). Pedicled vascularised bone grafts have also been reported more recently (19–21). Early and rigid internal fixation is typically advocated, frequently using a dorsally-applied compression screw. The advantages and disadvantages of limited open surgical approaches have been compared with fluoroscopically or arthroscopically-assisted percutaneous implant application in human patients, due to concerns regarding potential for fracture non-union (22–28).

Repair of canine radial carpal bone fractures using lag screws or pancarpal arthrodesis has been documented (3, 29). In dogs, the results of external support with resin or plaster casts are unpredictable, and in 13 cases managed conservatively, all progressed to a condition of osteoarthritis (2). Treatment by lag screw fixation has been reported to fail due to nonunion or screw breakage (3).

This study aimed to illustrate the application and clinical outcome of a variably-pitched, headless, tapered, cannulated, self-tapping and fully threaded compression screw for the treatment of two-piece oblique radial carpal bone fracture in five dogs.

Materials and methods

The medical and radiographic records of five dogs treated unilaterally for radial carpal bone fracture between September 2006 and April 2008 were reviewed. Thoracic limb lameness was present in all cases and was localised to the carpal joint based on presence of soft tissue swelling over the carpus, pain on manipulation, reduced range of motion, and exclusion of pain in other joints.

Clinical examination

Clinical examination was performed by one surgeon (NF) preoperatively, at two

and six weeks postoperatively and again at eight months to two years postoperatively. Examination included subjective evaluation of severity of lameness (graded 0–10,

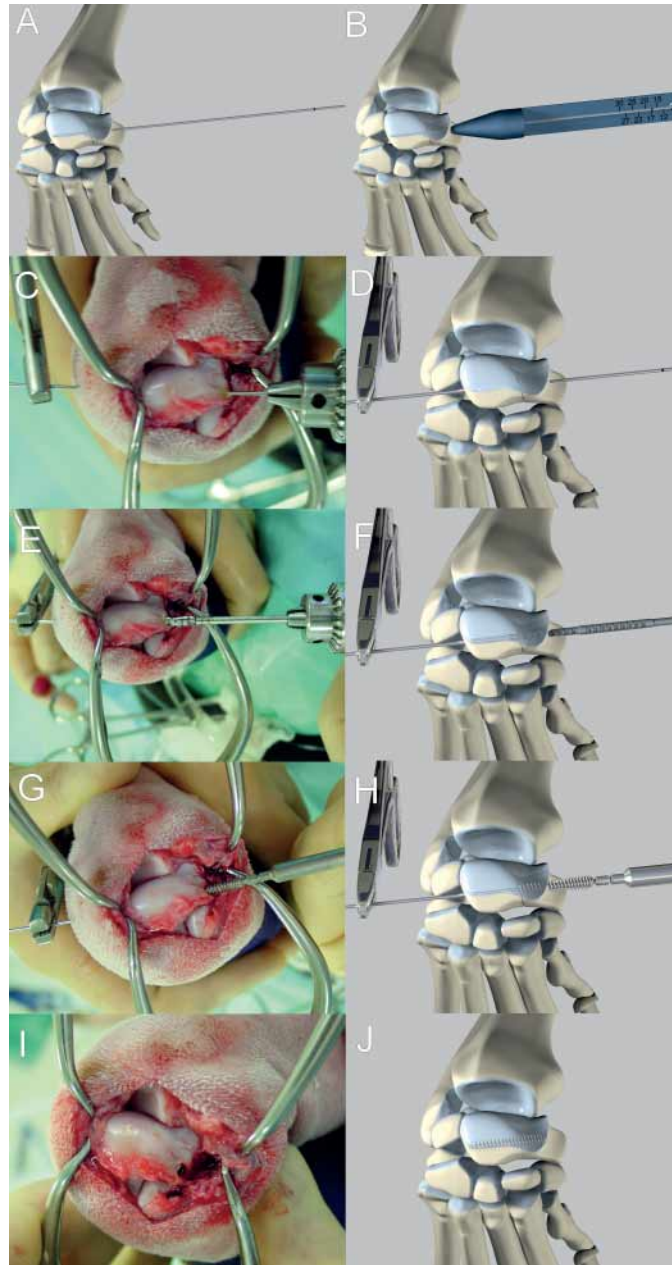


Fig. 1 Schematic representations and intraoperative photographs demonstrating surgical technique. A) Guide wire driven to engage but not breach the trans-cortex as close as possible to perpendicular relative to the fissure / fracture. For complete fractures, the fracture would be reduced and compressed using single-pointed fragment forceps (not shown) prior to placement of the guide wire. B) Graduated cannulated depth gauge threaded over wire to determine appropriate drilling depth and screw length. C and D) Guide wire driven through the trans-cortex and gripped laterally with forceps. E and F) Cannulated tapered drill bit deployed over the guide wire and advanced in 2–3 mm increments. Note etched calibration markings on the drill bit facilitating measurement of depth of drill insertion. G and H) Screw insertion over the guide wire using a cannulated hex driver. I and J) Screw countersunk beneath the bone surface and guide wire removed.

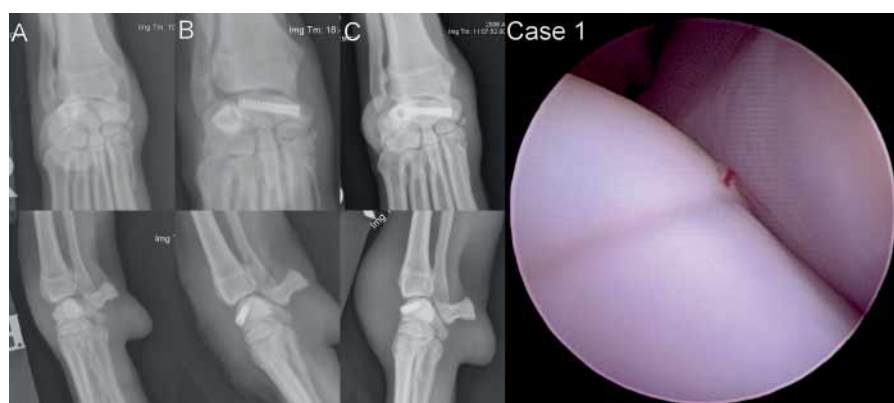

Fig. 2 Case 1 dorso-palmar (top) and medio-lateral (bottom) radiographs. A) Taken preoperatively. B) Taken six weeks postoperatively. C) Taken 12 months postoperatively. Preoperative radiographs document presence of the fissure plane in a typical location running from the centre of the radio-carpal joint proximally, toward the second carpal bone distally. Orthogonal views confirm acceptable implant placement approximately 30° to perpendicular to the fissure plane. Some loss of edge margin definition of the fissure plane is apparent 12 months postoperatively, but there is some persistent radiolucency suggestive of incomplete union. Marked dorsal soft tissue swelling is present. Preoperative arthroscopic image (far right) demonstrates appearance of the faintly discernable subchondral bone fissure with intact overlying cartilage.

with 0 representing normal and 10 non-weight-bearing lame), discomfort on manipulation of the carpus and other thoracic limb joints, carpal range of motion, and presence of palpable swelling or effusion. Pertinent findings were recorded.

Preoperative radiography

All dogs underwent radiographic examination of both carpal joints including medio-lateral and dorso-palmar views. Radiographs were also taken of both elbows (extended medio-lateral, flexed medio-lateral, cranio-caudal) and shoulders (medio-lateral, caudo-cranial) to exclude other potential causes of thoracic limb lameness.

Surgical technique

Surgical stabilisation of the radial carpal bone fracture was achieved by a single surgeon (NF) for all cases using headless, self-compressing cannulated screws^a. Free limb preparation was performed with the dogs

under general anesthesia; the dogs were positioned in sternal recumbence and the affected leg extended cranially with the carpus at the end of the table. Arthroscopy was performed prior to surgical repair in three cases. A standard dorsal approach to the carpus was made (30). The fat pad of the extensor carpi radialis tendon was trimmed to allow direct visibility of the radio-carpal joint. The synovial membrane was incised over the radio-carpal and middle carpal joints in order to facilitate assessment of articular cartilage integrity on all surfaces of the radial carpal bone. Maximal hyperflexion of the carpus enabled direct access to the proximo-dorsal surface of the radial carpal bone. Exposure was facilitated using appropriately positioned Gelpi and Hohmann retractors.

The fracture or fissure line was identified. Where fractures were complete, reduction plus interfragmentary compression was achieved with single-pointed bone-holding forceps^b applied to the medial and lateral aspects of the radial carpal bone; application was through the articular cartilage where the orientation of the fracture necessitated this. Extrinsic compres-

sion was not applied to incomplete fractures or fissure lines. A graduated guide wire was driven as close as possible to perpendicular relative to the fracture line from medial to lateral (typically approximately 15–30° oblique to the fracture line). The wire was driven so that it engaged but did not breach the trans-cortex (►Fig. 1A). A graduated cannulated depth gauge was threaded over the wire and held flush with the surface of the radial carpal bone to determine appropriate drilling depth and screw length (►Fig. 1B). The depth gauge was removed and the guide wire was then driven through the trans-cortex and gripped on the lateral aspect of the joint with forceps to avoid spin-out or binding during drilling (►Fig. 1C and 1D). A cannulated tapered drill bit of appropriate size was deployed over the guide wire and advanced in 2 to 3 mm increments, followed by repetitive retraction and lavage to remove any bone swarf or debris (►Fig. 1E and 1F). Etched calibration markings on the drill bit facilitated measurement of depth of drill insertion and care was taken that the drill did not penetrate the trans-cortex. Acutrak® standard screws were utilised in these cases. These screws taper from 3.3 mm at the leading tip to 3.8 to 4.6 mm in diameter at the 'head' (dependent on screw length) and are available from 12.5 mm to 30 mm in length at 2.5 mm increments. A screw 2 to 4 mm shorter than the measured depth was selected, threaded over the guide wire, engaged with a cannulated hex driver and finger-tightened by advancing three thread-widths in and two thread-widths out until firm resistance was felt (►Fig. 1G and 1H). Alternate advancement and retraction allowed the screw to cut its own threads without binding in the dense cancellous medulla of the radial carpal bone. The screw was countersunk beneath the bone surface (►Fig. 1I and 1J) and finally, the guide wire was removed and the peri-articular tissues were routinely closed.

Postoperative management

An external coaptation dressing was applied in all cases for two weeks and was changed once at two days postoperatively.

^a Acutrak® standard screws: Acumed®, Hillsboro, Oregon, USA

^b Bone holding forceps, Serial # 399.084: Synthes®, Paoli, PA, USA

Analgesia consisted of methadone^c 0.2 mg/kg intramuscularly q4–6h PRN or buprenorphine^d 0.02 mg/kg intramuscularly q8–12h PRN for the first 24 to 48 hours. Non-steroidal anti-inflammatory medication comprised either carprofen^e 4 mg/kg subcutaneously or meloxicam^f 0.2 mg/kg subcutaneously administered at induction of anaesthesia, and continued at 1–2 mg/kg orally q12h for carprofen or 0.1 mg/kg orally q24h for meloxicam for 14 to 28 days depending on response. Cage rest was enforced for six weeks with short leash-controlled walks three to six times daily.

Postoperative radiography

Immediate postoperative orthogonal radiography of the carpus was performed to assess fracture reduction and screw position. Radiography was repeated under routine deep sedation at six weeks, six months and longer-term (mean 12.5 months) postoperatively to evaluate progression of bone healing (► Fig. 2 to Fig. 5).

Results

Signalment, history and clinical examination

Five dogs with radial carpal bone fracture were treated between September 2006 and April 2008. Four dogs were Boxers, and one was a Labrador Retriever crossbreed. Three dogs were male, and two were female. All four Boxer dogs were aged between 1.2 and 2-years-old while the Labrador Retriever crossbreed was 5.5-years-old. Mean body weight was 25.5 kg (range 23.2 – 31.0 kg).

All of the dogs had a history of continuous or intermittent lameness, ranging from two to 75 weeks in duration prior to referral. The right thoracic limb was affected in two cases and the left in three. Lameness ranged from 4 out of 10 to 8 out of 10 in

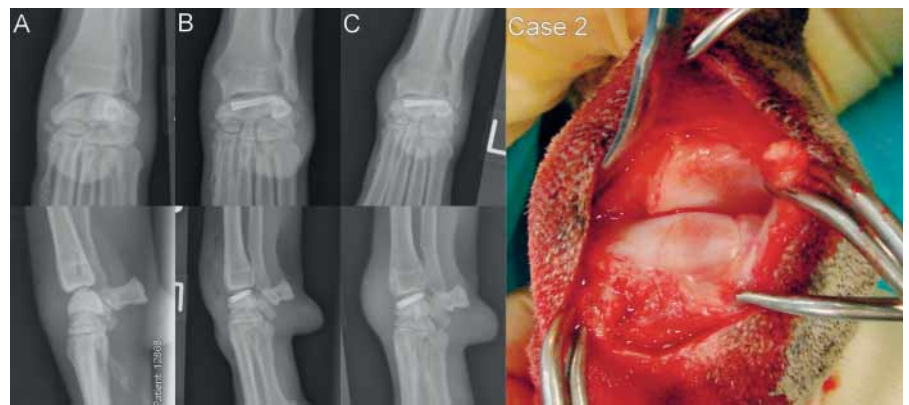


Fig. 3 Case 2 dorso-palmar (top) and medio-lateral (bottom) radiographs. A) Preoperatively. B) Immediately postoperatively. C) Eight months postoperatively. Orthogonal views confirm acceptable implant placement approximately 30° to perpendicular to the fissure plane. The fissure plane is no longer apparent eight months postoperatively. Moderate to marked dorsal soft tissue swelling is present. Intraoperative photograph (far right) demonstrates appearance of the faintly discernible subchondral bone fissure with intact overlying cartilage.

intensity, (median = 6/10) with zero representing normal and 10 non-weight-bearing lame. There was no reported history of trauma preceding clinical signs in any case (although this could not be definitively ruled out) and all dogs were affected by mild to moderate focal soft tissue swelling on the dorsal aspect of the radio-carpal joint. Pain on manipulation of the affected carpus was evident in all five cases, with crepitus also detected in one case (Case 2). Three dogs also demonstrated pain on elbow manipulation during physical examination. In two of these cases (Case 1 and Case 2) pain was evident bilaterally, while in one case (Case 5), pain was only evident affecting the contralateral elbow and lameness was not appreciated to be associated with this. Case 2 had been investigated four months previously for lameness of the right thoracic limb which was diagnosed as fracture of the radial carpal bone; due to comminution and marked pre-existing degenerative joint disease, treatment consisted of pancarpal arthrodesis. At this time, a slight radiolucent line was evident in the radial carpal bone of the left thoracic limb; however, as this was not causing any clinical symptoms, the decision was made to leave it untreated. At re-presentation four months later for left thoracic limb lameness, this radiolucent line was more clearly evident radiographically.

Preoperative radiography

All cases demonstrated an oblique incomplete fissure (Cases 1 and 2) or complete fracture (Cases 3, 4, 5) of the radial carpal bone, extending medially from the midpoint of the radio-carpal joint proximally to the level of the second carpal bone distally. A mild increase in radio-opacity consistent with subchondral bone sclerosis surrounding the fracture line was present in all patients. In Case 2, a further small fracture segment dorsal to the radial carpal bone, consistent with the comminuted 'T' fracture configuration, had been previously identified in the right carpus (managed by pancarpal arthrodesis as above), but a simple oblique incomplete fissure line alone was identified in the left carpus (3, 5). All patients with the exception of Case 3 demonstrated signs of mild elbow degenerative joint disease (including sub- or peritrochlear sclerosis or osteophytic new-bone at the caudo-dorsal aspect of the anconeal process up to 1 mm in depth).

Surgical findings

Arthroscopy of Case 5 revealed overt fracture of the radial carpal bone (► Fig. 5). Arthroscopy of Cases 1 and 2 revealed a faintly discernible subchondral bone fis-

^c Physeptone™: Martindale, Romford, UK

^d Vetergesic™: Reckitt Benckiser Healthcare, Hull, UK

^e Rimadyl™: Pfizer, Sandwich, UK

^f Metacam™: Boehringer Ingelheim, Rhein, Germany

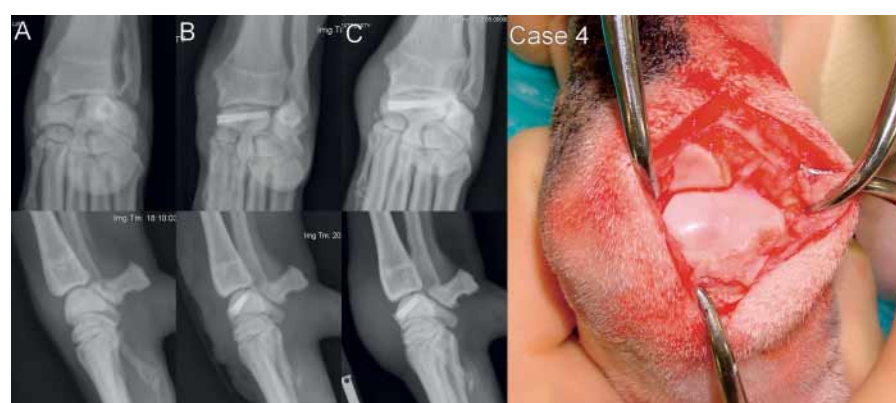

Fig. 4 Case 4 dorso-palmar (top) and medio-lateral (bottom) radiographs. A) Taken preoperatively. B) Immediately postoperatively. C) 24 months post-operatively. Orthogonal views confirm acceptable implant placement approximately 15° to perpendicular to the fissure plane. The fracture plane remains radiographically visible 22 months postoperatively, suggestive of incomplete osseous union. Moderate to marked dorsal and medial soft tissue swelling is present. Intraoperative photograph (far right) demonstrates appearance of the minimally displaced fracture line which includes fracture of overlying cartilage.

sure with intact overlying cartilage (►Fig. 2); however, the subchondral fissure was more apparent at arthrotomy when oblique indirect illumination was employed (►Fig. 3). In order to achieve this at arthrotomy, the light source from the arthroscope was held at an oblique angle to the presumed direction of the fissure, at a distance of approximately 2–3 cm. The fissure plane was evident as a subtle dark line beneath intact articular cartilage (►Fig. 3). Cases 3 and 4 did not undergo arthroscopy; both cases had complete fracture of the radial carpal

bone on arthrotomy (►Fig. 4). Surgical findings corroborated radiographic findings but also facilitated assessment of the integrity of the articular cartilage overlying the fissure or fracture. No dog underwent surgical elbow exploration at this time.

Clinical outcome

At six weeks postoperatively, lameness had resolved in all of the patients. All cases demonstrated palpable dorsal soft tissue swell-

ing at the surgical site. This swelling was firm and fibrous in nature, and was not painful upon manipulation or palpation. Carpal range of motion was reduced in all cases to approximately 90° flexion. Gait assessment of all cases at eight months to two years postoperatively (mean 12.5 months) did not reveal any visible lameness of any treated limb as assessed by a single clinician (NF) or by any owner. Case 2 was affected by moderate gait disturbance associated with pancarpal arthrodesis of the right thoracic limb. Clinical examination at follow-up revealed residual soft-tissue swelling on the dorsal aspect of the carpus for all operated limbs, but although carpal flexion was reduced, this did not have any apparent clinical ramifications and signs of pain were not evident for any case except when extreme forced flexion was attempted. All patients had returned to full-range exercise. When owners were asked at repeat examination if they perceived lameness affecting the operated limb, all answered no; when asked if they were satisfied with the procedure, all answered yes; when asked if they would have the operation performed again in similar circumstances, all answered yes.

Postoperative radiography

At six weeks, all patients demonstrated radiographic signs of early healing manifested by reduced definition of the edges of the original fissure or fracture line (►Fig. 2 and 5). Implants remained intact and there was no evidence of migration or lucency of contiguous bone. Soft tissue swelling was evident dorsally on the medio-lateral projection in all patients. At the radiographic follow-up examination (mean 12.5 months post-operatively), there were no implant-associated complications identified and three of five radial carpal bones did not have any discernable remnant of the radial-carpal fissure line (►Fig. 3 and 5). Radiolucency persisted in the region of the previous fissure or fracture line in Cases 1 and 4 (►Fig. 2 and 4) and was suggestive of incomplete osseous union, but in light of the positive clinical outcomes, no further investigations were performed.

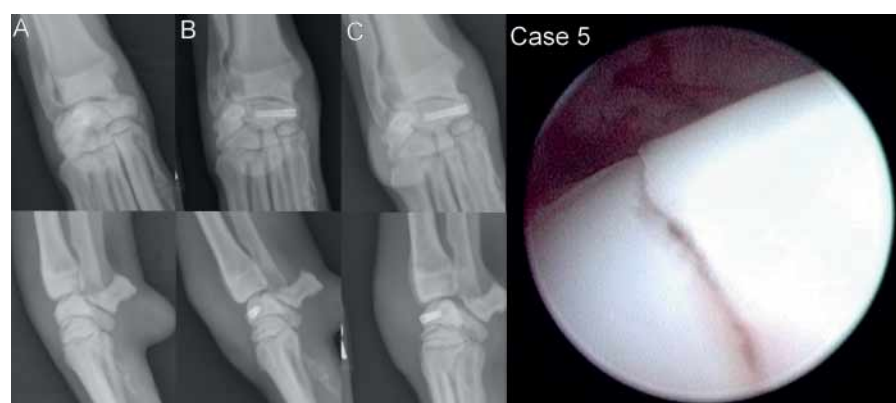

Fig. 5 Case 5 dorso-palmar (top) and medio-lateral (bottom) radiographs. A) Taken preoperatively. B) Six weeks postoperatively. C) 13 months postoperatively. Orthogonal views confirm acceptable implant placement approximately 15° to perpendicular to the fissure plane. The fracture plane shows some loss of edge margin definition at six weeks suggestive of early bone healing, and is no longer radiographically visible at 13 months suggestive of complete osseous union. Moderate dorsal soft tissue swelling is present. Preoperative arthroscopic image (far right) demonstrates appearance of the fracture line extending through the overlying articular cartilage.

Complications

Neutrophilic joint effusion, suspected to be septic in origin occurred in Case 1 four months postoperatively, and was associated with acute non-weight bearing lameness of the operated leg. Bacterial culture of joint fluid failed to reveal any pathogenic organisms, but lameness resolved rapidly after administration of cephalexin (20 mg/kg p/o BID for 6 weeks). Lameness recurred a further four months later and again resolved with a further six-week course of cephalexin. There was no radiographic evidence of bone lucency associated with the implant at any stage and infection had not recurred ten months later, whilst lameness had resolved and return to full-range exercise had been accomplished. However, complete radiographic union of the fissure line was not documented in this patient.

Discussion

Both surgical and non-surgical management of canine radial carpal fractures has been reported. In two studies of 15 and 13 cases respectively, all cases that were managed non-surgically with long-term follow-up manifested radiographically documented progression of osteoarthritis and persistent lameness was a common feature (2, 6). Secondary osteoarthritis probably develops as a consequence of the articular fissure or fracture and the resultant instability (2). Therefore, there may be rationale for prompt surgical intervention, justifying surgical intervention in this case series. In human patients, delayed treatment led to increased incidence of non-union and persistent pain despite repair due to severe osteoarthritis, with increased time from diagnosis to treatment being a risk factor for non-union (21, 31, 32). Furthermore, there may be rationale for early stabilisation of incomplete canine radial carpal bone fissures to help prevent progression to catastrophic fracture (as seen in the right thoracic limb of Case 2).

Identification of subtle, undisplaced fissures may prove elusive using conventional radiography or even arthroscopy, especially if the fissure has not penetrated the articular cartilage, as has been the experience

with human scaphoid fractures (23). In Cases 1 and 2, arthroscopy revealed a faintly discernable subchondral bone fissure with intact overlying cartilage, and it is worth noting that the fissure was more clearly apparent as a subtle dark line beneath intact articular cartilage when oblique indirect illumination was employed at arthrotomy. This configuration could be consistent with an aetiopathogenesis of incomplete ossification of the radial carpal bone, or alternatively, would also be consistent with an aetiopathogenesis of stress fracture. A similar oblique indirect illumination technique has previously been described for identification of subchondral fissures of the medial aspect of the coronoid process of the ulna (subsequently confirmed by histomorphometry) without penetration of the articular cartilage (33). However, in such cases advanced imaging modalities such as computed tomography or magnetic resonance imaging may prove useful (21). Both modalities have been used in human patients to differentiate congenital variants from pseudoarthroses following injury (31).

Failure of complete radiographic union in two out of five dogs in this study was an interesting finding, and may mirror the recognised feature of non-union associated with transcondylar screw placement for management of incomplete ossification of the humeral condyle (34–37). Similarly, it is unknown whether this is a feature of poor local blood supply as in the human scaphoid, persistent instability as has been proposed for the humeral condyle, or other currently unidentified factors (13, 38). These factors should be considered during the surgical approach, as well as the potential for damage to surrounding soft tissues and vasculature that could compromise bone healing. The feasibility of percutaneous application of cannulated screws under fluoroscopic or even arthroscopic guidance warrants investigation, although technical and equipment limitations may compromise widespread usage (21–24). Interestingly, duration of lameness preoperatively did not appear to be a significant predisposing factor to non-union in this case series, although the identification of a radiolucent line in Case 1 several months previous, and in the absence of overt lame-

ness on this limb at that time, could intimate a longer chronology of disease than identified, and could hypothetically have been a predisposing variable to non-union in this case. The possibility of subsequent implant failure should be considered in cases of non-union, and further investigation and ongoing long-term monitoring of clinical cases is warranted in this regard.

Several different bone screws have been used for scaphoid fracture repair in humans, including Acutrak[®], Asnis III[®], Herbert^{TM[h]}, Herbert-Whipple^{TM[h]}, Synthes Cannulated Screw Systemⁱ and most recently the bioresorbable LG (Little Grafters)TM screws^j. Superior compressive forces have been found to be provided by Acutrak[®] and LGTM screws (39, 40). Acutrak[®] screws are headless, self-compressing screws which achieve reliable compression, even in small bone fragments, without the difficulties of accurate over-drilling in minimally displaced or incomplete fractures required for conventional compression screw placement. Successful use of Acutrak[®] screws has previously been documented in dogs for fixation of ununited anconeal process and incomplete ossification of the humeral condyle (41, 42). The variable pitch of the screw threads induces compression as the screw is inserted, creating a more gradual increase to peak compression without the abrupt loss of holding power that is associated with conventional cortical screws inserted in lag fashion (43). Cannulation over a guide-wire allows for reproducible and accurate implant placement, and it helps maintain fracture reduction during drilling and depth measurement, allowing one to aim the screw placement as close to perpendicular to the fracture line as possible; this is analogous to the 'sweet spot' referred to by human surgeons treating scaphoid fractures (23, 44). In contrast to conventional lag screws, the threads of the Acutrak[®] screw engage both the near and far fracture segments leading to increased screw-bone contact which maximises pull-out strength and may increase fatigue strength. Furthermore, ab-

^g Stryker, Mahwah, NJ, USA

^h Zimmer Inc., Warsaw, IN, USA

ⁱ Synthes, Paoli, PA, USA

^j Biocomposites Inc., Wilmington, NC, USA

sence of a glide hole within which the screw could theoretically translate means that application of the screw perfectly perpendicular to the fracture plane is not essential as translation of the bone segments is not an intrinsic risk. This was beneficial within this clinical application where attainment of perfect perpendicularity would have been extremely challenging. Compression achieved by the Acutrak® screw has been shown to be comparable or superior to other commonly used screw types (40, 44, 45). Because canine bone does not have the same elastic modulus or canalicular density as human bone, it is our experience that insertion of the Acutrak® screw in canine bone can be more challenging than in human bone, and that greater potential for thermal necrosis exists when drilling, so appropriate irrigation is mandatory (46).

Although mild to moderate soft tissue swelling was evident over the carpus preoperatively, this sequel did not produce discernable gait disturbance by six weeks postoperatively. Similar findings have been reported postoperatively in studies of radial carpal bone luxation (47, 48). We postulated that the swelling and reduction in range of movement was primarily attributable to the surgical approach. Percutaneous application of Acutrak® screws under fluoroscopic guidance may help reduce postoperative periarticular swelling in future cases (22, 27, 49).

Other complications are possible, but were not encountered in these cases with the exception of suspected sepsis in one case. Early leash-controlled exercise was encouraged because incidence of non-union in human scaphoid fractures increased with prolonged immobilisation (31). Screw breakage might necessitate implant removal, which could be more challenging with the subcortically-placed Acutrak® screws than with conventional cortical screws.

A limitation in this study is the undetermined contribution of elbow pathology to the initial lameness. Three of the five cases reported demonstrated evidence of pain on elbow manipulation preoperatively, and four of the five cases had radiographic evidence of elbow disease. This was not investigated further or specifically treated in any case at this time, although the authors recognise that

clinical improvements may have been partially or completely due to effective medical therapy for osteoarthritis of the elbow. In order to evaluate this further, use of this technique would be required in a cohort of dogs without evidence of elbow disease.

No previously published technique has been consistently successful for treatment of radial carpal bone fissure or fracture in dogs. While results of more conservative therapies remain unpredictable, lag-screw fixation has been associated with complications necessitating future pancarpal arthrodesis. All dogs treated by Acutrak® screw fixation demonstrated either progressive radiographic healing or apparent fracture stability and remission of lameness at six weeks postoperatively. Osseous union was achieved in three out of five dogs with restoration of integrity and stability without residual pain or lameness at the long-term follow-up, thus intimating successful outcome. However, direct comparison between this study and others is complicated as all other studies include a variety of fracture configurations while this study population was affected only by two-piece oblique fissures or fractures of the radial carpal bone. Morbidity was minimal, and was acceptable for clinical application. In our experience, Acutrak® screw fixation of canine radial carpal fracture proved a reliable alternative to conventional compression screw fixation and may have benefits over alternatives, attributable to screw design and application technique.

Acknowledgements

The authors would like to thank Mr Tim Vojt for the rendering of images 1A, 1B, 1D, 1E, 1H and 1J, and Miss Sarah Girling, Mr Michael Hamilton and Dr Dylan Clements for their contributions and assistance with preparation of the manuscript.

References

1. Vaughan LC. Disorders of the carpus I and II. *British Vet Jour* 1985; 141: 332–341; 453–456.
2. Li A, Bennett D, Gibbs G, et al. Radial carpal bone fractures in 15 dogs. *J Small Anim Pract* 2000; 41: 74–79.
3. Tomlin JL, Peard M, Langley-Hobbs SJ, et al. Radial carpal bone fracture in dogs. *J Am Anim Hosp Assoc* 2001; 37: 173–178.

4. Denny HR, Butterworth SJ. *A Guide to Canine and Feline Orthopaedic Surgery*. 4th Ed. Oxford, UK: Blackwell Science Ltd.; 2000. 413.
5. Johnson AL, Houlton JEF, Vannini R. Chapter 5: Fractures of the maxilla. In: *AO Principles of Fracture Management in the Dog and Cat*. 2nd ed. Stuttgart, Germany: AO Publishing, Georg Thieme Verlag; 2005. 341.
6. Johnson KA. Carpal injuries. In: Bloomberg MS, Dee JF, Taylor RA, eds. *Canine sports medicine and surgery*. Philadelphia: WB Saunders, 1998: 100–119.
7. Gnudi G, Mortellaro CM, Bertoni G, et al. Radial carpal bone fracture in 13 dogs. *Vet Comp Orthop Traumatol* 2003; 16: 178–183.
8. Gnudi G, Martini FM, Zanichelli S. Incomplete humeral condylar fracture in two English Pointer dogs. *Vet Comp Orthop Traumatol* 2005; 18: 243–245.
9. Marcellin-Little DJ, Deyoung DJ, Ferris KK, et al. Incomplete ossification of the humeral condyle in Spaniels. *Vet Surg* 1994; 23: 475–487.
10. Mikic D, Ercegan G, Somer T. Detailed anatomy of the antebrachio-carpal joint in dogs. *Anat Rec* 1992; 233: 329–334.
11. Doman AN, Marcus NW. Congenital bipartite scaphoid. *J Hand Surg Am* 1990; 15A: 869–873.
12. Akahane M, Ono H, Sada M, et al. Bilateral bipartite lunate: A case report. *J Hand Surg Am* 2002; 27A: 355–359.
13. Louis DS, Calhoun TP, Garn SM, et al. Congenital bipartite scaphoid – fact or fiction? *J Bone Joint Surg* 1976; 58A: 1108–1112.
14. Mahon A, Craigen M. Fractures and dislocations of the carpus. *Surgery* 2006; 24: 433–436.
15. Stark HH, Tickard TA, Zemel NP, et al. Treatment of ununited fractures of the scaphoid by iliac bone grafts and Kirschner-wire fixation. *J Bone Joint Surg* 1988; 70: 982–991.
16. Green DP. The effect of avascular necrosis on Russe bone grafting for scaphoid nonunion. *J Hand Surg* 1985; 10A: 597–605.
17. Gelberman RH, Wolock BS, Siegel DB. Fractures and non-unions of the carpal scaphoid. *J Bone Joint Surg Am* 1989; 71: 1560–1565.
18. Fernandez DL. A technique for anterior wedge-shaped grafts for scaphoid nonunions with carpal instability. *J Hand Surg* 1984; 9A: 733–737.
19. Mathoulin C, Haerle M. Vascularized bone graft from the palmar carpal artery for treatment of scaphoid nonunion. *J Hand Surg* 1998; 23: 318–323.
20. Straw RG, Davis TRC, Dias JJ. Scaphoid nonunion: Treatment with a pedicled vascularised bone graft based on the 1,2 intercompartmental suprapetinar branch of the radial artery. *J Hand Surg* 2002; 27: 413–416.
21. Shin AY, Bishop AT. Pedicled vascularised bone grafts for disorders of the carpus: scaphoid nonunion and Kienbock's disease. *J Am Acad Orthop Surg* 2002; 10: 210–216.
22. Slade JF, Gutow AP, Geissler WB. Percutaneous internal fixation of scaphoid fractures via an arthroscopically assisted dorsal approach. *J Bone Joint Surg Am* 2002; 84: 21–36.
23. Slade JF, Grauer J, Mahoney J. Arthroscopic reduction and percutaneous fixation of scaphoid fractures with a novel dorsal technique. *Orthop Clin North Am* 2003; 32: 247–261.
24. Sommerkamp T. Scaphoid AARIF: Arthroscopically assisted reduction and internal fixation of scaphoid fractures. *Hand Surg* 2003; 1: 192–210.

25. Bond CA, Shin AY, McBride MT, et al. Percutaneous screw fixation or cast immobilization for nondisplaced scaphoid fractures. *J Bone Joint Surg Am* 2001; 83A: 483–488.
26. Bushnell BD, McWilliams AD, Messer TM, et al. Complications in dorsal percutaneous cannulated screw fixation of nondisplaced scaphoid wrist fractures. *Hand Surg* 2007; 32: 827–833.
27. Bedi A, Jebson PJ, Hayden RJ, et al. Internal fixation of acute nondisplaced scaphoid waist fractures via a limited dorsal approach: An assessment of radiographic and functional outcomes. *Hand Surg* 2007; 32: 326–329.
28. Adamany DC, Mikole EA, Frazer BJ. Percutaneous fixation of the scaphoid through a dorsal approach: An anatomic study. *Hand Surg* 2008; 33: 327–331.
29. Whitelock R. Conditions of the Carpus in the Dog. *In Pract* 2001; 23: 2–13.
30. Piermattei DL, Johnson KA. *An Atlas of Surgical Approaches to the Bones and Joints of the Dog and Cat*. 4th Ed. Pennsylvania, USA: Saunders; 2004. 254–275.
31. Schuind F, Haenkjens P, Van Innis F, et al. Prognostic factors in the treatment of carpal scaphoid nonunions. *J Hand Surg Am* 1999; 24: 761–776.
32. Southcott R, Rosman MA. Non-union of carpal scaphoid fractures in children. *J Bone Joint Surg Br* 1977; 59(B): 20–23.
33. Fitzpatrick N. Clinical and radiographic assessment of 83 cases of subtotal coronoid osteotomy (SCO) for treatment of fragmented medial coronoid process (FMCP). VOS Spring meeting, Big Sky, MT, USA. 2004.
34. Butterworth SJ, Innes JF. Incomplete humeral condylar fractures in the dog. *J Small Anim Pract* 2001; 42: 394–339.
35. Gundi G, Martini FM, Zannicheli S, et al. Incomplete humeral condylar fracture in two English Pointer dogs. *Vet Comp Orthop Traumatol* 2005; 18: 243–245.
36. Kaderly RE, Lamothe M. Incomplete humeral condylar fracture due to minor trauma in a mature Cocker Spaniel. *J Am Anim Hosp Assoc* 1992; 28: 361–364.
37. Marcellin-Little DJ, DeYoung DJ, Ferris KK, et al. Incomplete ossification of the humeral condyle in Spaniels. *Vet Surg* 1994; 23: 475–487.
38. Charles AE, Ness MG, Yeadon R. Failure mode of transcondylar screws used for treatment of incomplete ossification of the humeral condyle in 5 dogs. *Vet Surg* 2009; 38: 185–191.
39. Beadel G, Ferreira L, Johnson JA, et al. Interfragmentary compression across a simulated scaphoid fracture – Analysis of 3 screws. *J Hand Surg* 2004; 29: 273–278.
40. Bailey CA, Kuiper JH, Kelly CP. Biomechanical evaluation of a new composite bioresorbable. *J Hand Surg Br* 2006; 31: 208–212.
41. Fitzpatrick N, Farrell M, O'Riordan J, et al. Application of a self-compressing headless variably pitched cannulated screw for treatment of ununited anconeal process in dogs. 13th ESVOT Congress, Munich, Germany 2006. 7th – 10th September. Pp 225.
42. Fitzpatrick N, Smith TJ, O'Riordan J, et al. Treatment of incomplete ossification of the humeral condyle with autogenous bone grafting techniques. *Vet Surg* 2009; 38: 173–184.
43. Wheeler DL, McLoughlin SW. Biomechanical assessment of compression screws. *Clin Orthop Relat Res* 1998; 350: 237–245.
44. Bueno ACD, Galuppo LD, Taylor KT, et al. A biomechanical comparison of headless tapered variable pitch and AO cortical bone screws for fixation of a simulated slab fracture in equine third carpal bones. *Vet Surg* 2003; 32: 167–177.
45. Toby EB, Butler TE, McCormack TJ, et al. Comparison of fixation screws for the scaphoid during application of cyclical bending loads. *J Bone Joint Surg* 1997; 79A: 1190–1197.
46. Choi K, Khang G, Goldstein SA. The elastic moduli and fatigue properties of canine trabecular bone tissue: Special issue in biomechanics. *KSME International Journal* 2001. 15(7): 1022–1031.
47. Miller A, Carmichael S, Anderson TJ, et al. Luxation of the radial carpal bone in four dogs. *J Small Anim Pract* 1990; 31: 148–154.
48. Punzet G. Luxation of the os carpi radiale in the dog – pathogenesis, symptoms, and treatment. *J Small Anim Pract* 1974; 15: 751–756.
49. Klein DM, Belsole RJ. Percutaneous treatment of carpal, metacarpal, and phalangeal injuries. *Clin Orthop Relat Res* 2000; 375: 116–125.