

# Distal femoral lateral closing wedge osteotomy as a component of comprehensive treatment of medial patellar luxation and distal femoral varus in dogs

Barry E. Brower<sup>1</sup>; Michael P. Kowaleski<sup>2</sup>; Ann M. Peruski<sup>3</sup>; Antonio Pozzi<sup>4</sup>; Jonathan Dyce<sup>5</sup>; Kenneth A. Johnson<sup>6</sup>; Randy J. Boudrieau<sup>2</sup>

<sup>1</sup>Veterinary Medical Center of Long Island, West Islip, NY, USA; <sup>2</sup>Department of Clinical Sciences, Cummings School of Veterinary Medicine, Tufts University, North Grafton, MA, USA; <sup>3</sup>Care Center, Cincinnati, OH, USA; <sup>4</sup>Vetsuisse Faculty, University Zurich, Zurich, Switzerland; <sup>5</sup>Department of Veterinary Clinical Sciences, Ohio State University, Columbus, OH, USA; <sup>6</sup>Faculty of Veterinary Science, School of Life and Environmental Sciences, University of Sydney, Sydney, NSW, Australia

## Keywords

Medial patellar luxation, femoral varus, distal femoral osteotomy

## Summary

**Objective:** To describe a cohort of dogs with medial patellar luxation managed with a distal femoral lateral closing wedge osteotomy (DFO) as a component of comprehensive treatment, and to report radiographic and long-term clinical outcome of this technique.

**Methods:** Medical records of dogs that had a lateral closing wedge DFO as part of management of medial patellar luxation at three veterinary teaching hospitals were reviewed. Surgical reports as well as the preoperative, postoperative, and follow-up radiographs were reviewed. The anatomical lateral distal femoral angle (aLDFA) was determined. Long-term clinical outcome was assessed by telephone interview with the owner.

**Results:** A lateral closing wedge DFO was performed on 66 limbs. The mean pre- and postoperative aLDFA was  $107.6^\circ \pm 5.8^\circ$  and  $94.1^\circ \pm 4.2^\circ$ , respectively. Cranial cruciate ligament disease was identified in 28/66 affected limbs. Tibial angular deformity, torsional deformity, or both was identified in nine of the 66 limbs. Osteotomy healing was confirmed radiographically in 51/66 limbs. The mean time to union was  $73 \pm 37$  days. All patellae were in the normal position and stable. Complications included infection (2/51), fixation failure (1/51), delayed healing (2/51), and persistent lameness (1/51).

**Clinical significance:** In this cohort of cases, DFO was a highly successful and repeatable component of surgical treatment for dogs with medial patellar luxation associated with femoral varus. This study also provides more evidence of the high rate of concurrent cranial cruciate ligament disease in cases of medial patellar luxation complicated by femoral varus, and supports an association between stifle instability and medial patellar luxation.

## Correspondence to:

Michael P. Kowaleski, DVM, Diplomate ACVS/ECVS  
Department of Clinical Sciences  
Cummings School of Veterinary Medicine at Tufts University  
200 Westboro Road  
North Grafton, MA 01536, USA  
Phone: +1 508 887 4659  
E-mail: mike.kowaleski@tufts.edu

Vet Comp Orthop Traumatol 2017; 30: 20–27

<https://doi.org/10.3415/VCOT-16-07-0103>

Received: July 14, 2016

Accepted: August 1, 2016

Epub ahead of print: December 9, 2016

## ORCID iD:

KAJ: <http://orcid.org/0000-0001-6207-3924>

Supplementary Material to this article is available online at <https://doi.org/10.3415/VCOT-16-07-0103>

\* Note: The reviewing and processing of this paper was fully conducted by the Deputy Editor-in-Chief Simon Roe, and was completely independent of any involvement of the Editor-in-Chief. Original Submission received under a different manuscript number on April 20, 2016.

## Introduction

Medial patellar luxation is a commonly diagnosed cause of lameness in dogs, the prevalence of which appears to be increasing in large breeds (1–7). Multiple surgical treatments for medial patella luxation have

been described with the goals of re-aligning the extensor mechanism and, when deemed necessary, deepening the trochlear sulcus (8, 9). This has classically been accomplished through local treatments including tibial tuberosity transposition, trochlear wedge recession or trochlear

block recession techniques, and soft tissue balancing procedures (8). The rate of recurrence of patellar luxation following these procedures has been reported to be between 8% and 48%, and recurrence has been reported to occur more frequently in large breeds of dogs (2, 6, 10).

The importance of distal femoral varus in the pathophysiology of medial patella luxation is becoming increasingly evident (2, 11–16). If excessive femoral varus is present, failure to correct it has been proposed as a cause of postoperative recurrence of medial patellar luxation in large breed dogs. Consequently, surgical treatment of medial patellar luxation has recently focused on correcting excessive femoral varus with femoral corrective osteotomy (11, 12, 16, 17).

The objectives of this study were: 1) to report on a cohort of dogs with femoral varus and associated medial patellar luxation (breed predilection, magnitude of femoral varus, grade of luxation, concurrent orthopaedic disease); 2) describe the surgical technique of corrective lateral closing wedge distal femoral osteotomy (DFO) for treatment of femoral varus and medial patellar luxation; and 3) to report on the postoperative radiographic and clinical outcomes of this technique in this cohort of patients.

## Material and methods

### Criteria for case selection

Medical records of dogs treated for medial patellar luxation by lateral closing wedge DFO at The Ohio State University Veterinary Teaching Hospital from October 2000 to October 2005, the Cummings Veterinary Medical Center at Tufts University from July 2007 to January 2011, and the University of Florida Small Animal Hospital from August 2008 to August 2012 were reviewed. Surgical reports, pre- and postoperative radiographs and computed tomography (CT) scans (if available), as well as follow-up radiographs were evaluated. Patient signalment, grade of medial patellar luxation, pre- and postoperative anatomical lateral distal femoral angle (aLDFA), femoral torsion abnormalities, tibial angular and torsional abnormalities, and concurrent orthopaedic conditions were recorded. Pre- and postoperative aLDFA were determined by the primary clinician for patients treated after 2007, and retrospectively by the investigators for earlier cases using a previously described method (18). In-hospital re-evaluation of patellar stability and time to radiographic healing were reviewed.

### Surgical planning

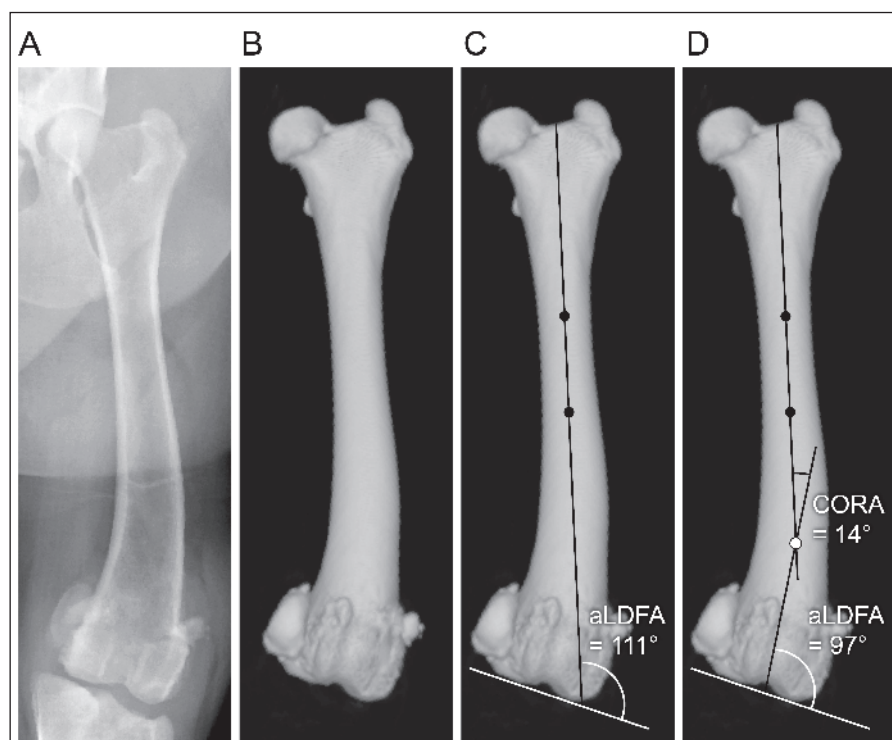
Standard craniocaudal radiographs (hip extended view or craniocaudal femur view) or CT (if available), as well as mediolateral views of the femur, together with axial views of the femur in some cases, were obtained to identify distal femoral varus, and femoral torsion, respectively (19). Radiographs were screened for acceptability based on standardized methods (19). Preoperative determination of femoral varus was obtained by measuring the femoral varus angle (FVA). In limbs with suspected stifle pathology, tibial angular deformity, or both together (based on clinical examination), orthogonal radiographs (or CT) of the tibia, including the stifle and talocrural joints, also were obtained, and the deformity quantified as previously described (19).

After 2007, preoperative femoral varus deformity was quantified by measuring the aLDFA on craniocaudal radiographs, or

three-dimensional reconstructions of CT images of the femur (► Figure 1 A-D); this was compared to the published reference angles for dogs of the same breed without limb deformities, or to the opposite limb in dogs with unilateral deformities (18). Surgical planning was performed by the attending surgeon based upon the magnitude of distal femoral varus as well as the presence of any other angular or torsional deformities, co-existing abnormalities associated with patellar luxation, or accompanying cranial cruciate ligament insufficiency, meniscal pathology, or both together, with a goal of treating all underlying abnormalities based on current treatment guidelines (19).

### Pre- and postoperative care

All patients were premedicated and anaesthetized following a protocol selected by the attending anaesthetist. Cefazolin sodium (22 mg/kg IV) was administered to



**Figure 1** A) Craniocaudal radiographic view of the femur. B) Three-dimensional volumetric reconstruction of the femur of the same patient. C) Three-dimensional volumetric reconstruction of the femur with the anatomical lateral distal femoral angle (aLDFA) measured (aLDFA = 111°). D) Three-dimensional volumetric reconstruction of the femur with the centre of rotation of angulation (CORA) identified (white circle, CORA magnitude = 14°) using the breed specific aLDFA of 97° degrees for this Labrador Retriever.

all patients at induction and every two hours perioperatively. While hospitalized, postoperative analgesics were administered at the discretion of the primary surgeon. Non-steroidal anti-inflammatory drugs were administered in the early postoperative period, generally for seven to 10 days. Cephalexin (22 mg/kg per os q8–12h) was administered postoperatively at the discretion of the surgeon. Dogs were discharged to the owners two to four days after surgery with instructions for strict exercise restriction until re-examination with radiographic assessment of healing six to eight weeks later.

### Surgical technique

Surgery was performed with the patient positioned in dorsal recumbency. The affected limb was aseptically prepared and draped to provide full access to the limb from the proximal diaphysis of the femur to the paw. A lateral surgical approach to the stifle joint and distal femur was performed. The DFO site (lateral closing wedge) was planned to ensure that the distal femoral segment was large enough to accommodate at least three plate screws without interference of the implants with the stifle joint.

A tibial plateau levelling osteotomy (TPLO) jig was applied to the cranial aspect of the femur with the distal pin immediately proximal to the cartilage of the trochlear groove, and the proximal pin within the span of the planned bone plate. The frame of the jig was placed medially. The jig pins were placed in the sagittal plane, parallel to the trochlear groove of the femur.

The closing wedge angle of the osteotomy was based on preoperative planning (17, 19). A coplanar, lateral closing wedge osteotomy was completed, and the proximal and distal segments reduced. If torsional abnormality was present (based on preoperative measurements or intra-operative assessment), correction was accomplished by bending the distal jig pin in the frontal plane with hand-held plate bending pliers; the angular bend in the pins or divergent angle between the two jig pins was measured with a goniometer to confirm that the correction had been accurately

performed. Two Kirschner wires were placed from distolateral to proximomedial and distomedial to proximolateral to maintain reduction, avoiding the area of bone plate application.

An appropriately sized (6 to 9-hole) bone plate was contoured and applied to the lateral aspect of the femur, ensuring that the implants did not interfere with stifle joint function based on intra-operative examination. The distal screws were placed into the caudal aspect of the femur or femoral condyle to ensure they would not interfere with the trochlear wedge recession or trochlear block recession procedure, or these screws were placed after the recession technique was performed. In many later cases, the second most distal screw was placed as a temporary monocortical screw, and the distal screw was not placed until after the recession was completed, at which time the monocortical screw was replaced with a bicortical screw and the distal screw was placed; these screws penetrated the recessed osteochondral trochlear wedge or block. The osteotomized wedge of the distal femur was morselized and these cortico-cancellous bone chips were placed as an autogenous bone graft at the osteotomy site in many cases (►Figure 2, B and C) at the discretion of the surgeon.

Ancillary procedures such as a trochlear wedge recession, tibial tuberosity transposition, and soft-tissue balancing were performed at the discretion of the surgeon based on the depth of the trochlear groove and patellar ligament alignment. In cases of concurrent partial or complete rupture of the cranial cruciate ligament, either a TPLO procedure, a tibial closing wedge osteotomy, a tibial tuberosity advancement, or a lateral fabellotibial suture technique was used for extracapsular stabilization (19). In cases where tibial valgus or torsion was present, closing wedge osteotomy or transverse osteotomies with torsional correction were performed, respectively. With simultaneous internal tibial torsion and medial displacement of the tibial tuberosity, a TPLO procedure with internal tibial torsion correction was utilized to stabilize the stifle and lateralize the tibial tuberosity as previously described (20). In cases of concurrent tibial angular and torsional de-

formities, closing wedge osteotomy with or without TPLO, depending on cranial cruciate ligament status, was performed with torsional correction as indicated (21).

Radiographs of the femur, and the tibia if warranted, were obtained postoperatively. Postoperative varus (either FVA or aLDFA) and implant placement were assessed (►Figure 2 A-C). A modified Robert Jones bandage was applied to the affected limb of all dogs for the first 36–72 hours.

### Follow-up

In-hospital re-evaluation and radiographic evaluation were performed at scheduled appointments six to eight weeks postoperatively. At the time of each re-examination, patellar stability, gait, and limb function at a walk or trot were assessed. Radiographic healing was retrospectively assessed using grading criteria developed by the International Society of Limb Salvage (►Figure 2 D and E) (22). In this grading system, the scores are defined as follows: 1 = poor union, with less than 25% healing (no evidence of callus), 2 = fair union with 25–50% healing, 3 = good union with >50–75% healing, and 4 = excellent union with greater than 75% healing. If radiographic healing was not adequate in the opinion of the attending clinician at the first re-examination, further follow-up and radiographic evaluation was performed.

Long-term follow-up was obtained by a telephone interview at the time of data collection for this report, using standardized questions (►Telephone Questionnaire: available online with the Supplementary Material at <http://www.vcot-online.com>). Owners were asked to evaluate the dog's lameness in different scenarios (e.g. walking, running, jumping), ability to tolerate exercise, their impression of the success of the surgery, and whether or not they would have the surgery performed again under the same circumstances. In cases in which both hindlimbs were treated, owners were asked to evaluate each procedure individually. Owners were also asked to report any complications or subsequent surgery performed on the stifle joint since the original surgery.

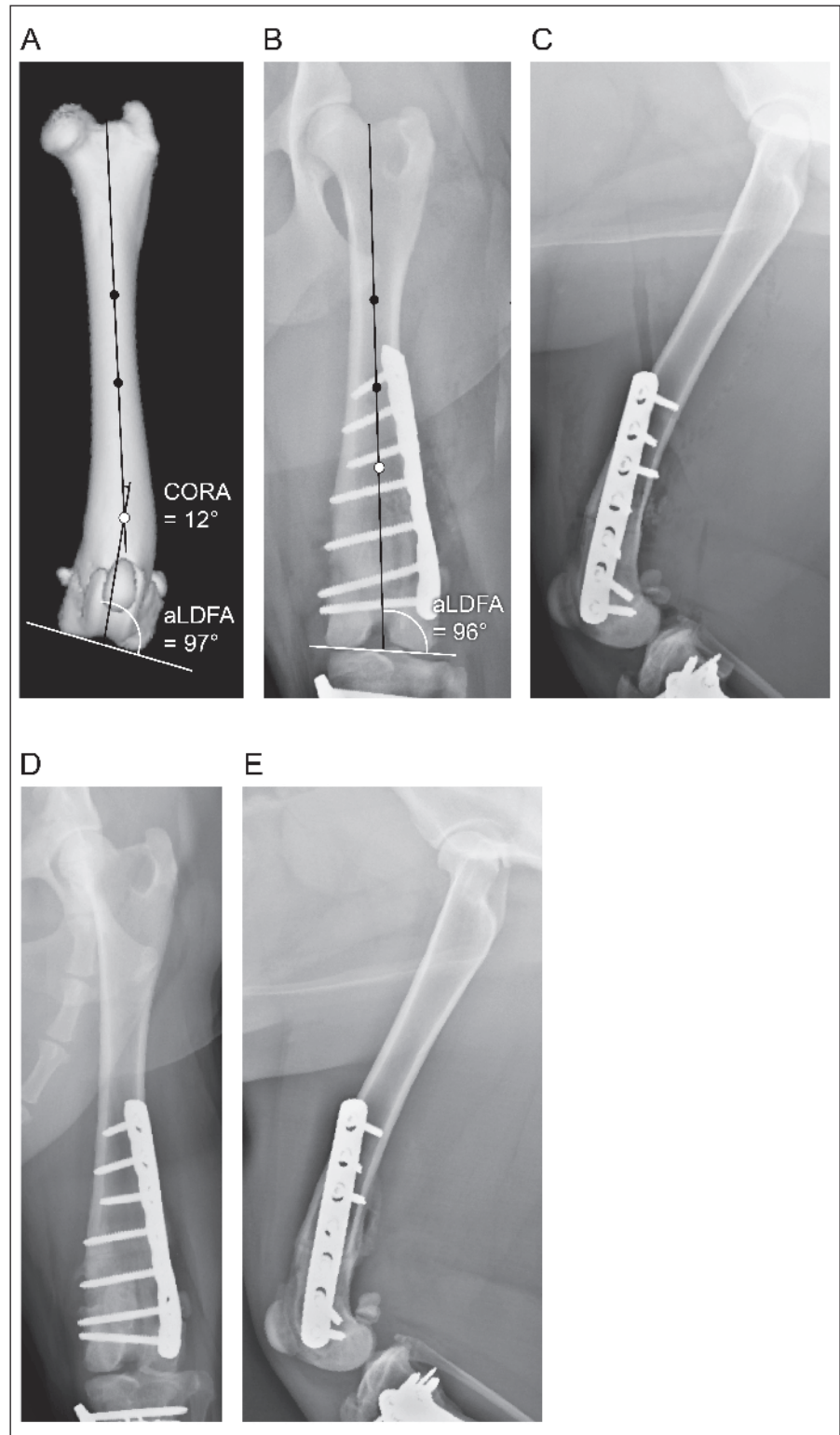
## Results

Fifty-five dogs satisfied the inclusion criteria for the study. The most common breed was the Labrador Retriever (15/55), and all but nine dogs were large breeds. Most dogs were young, with a mean age of  $2.1 \pm 1.5$  years at presentation (range: 5 months to 9.5 years). Gender was evenly distributed, and almost all were neutered (► Appendix Table 1: available online at [www.vcot-online.com](http://www.vcot-online.com)).

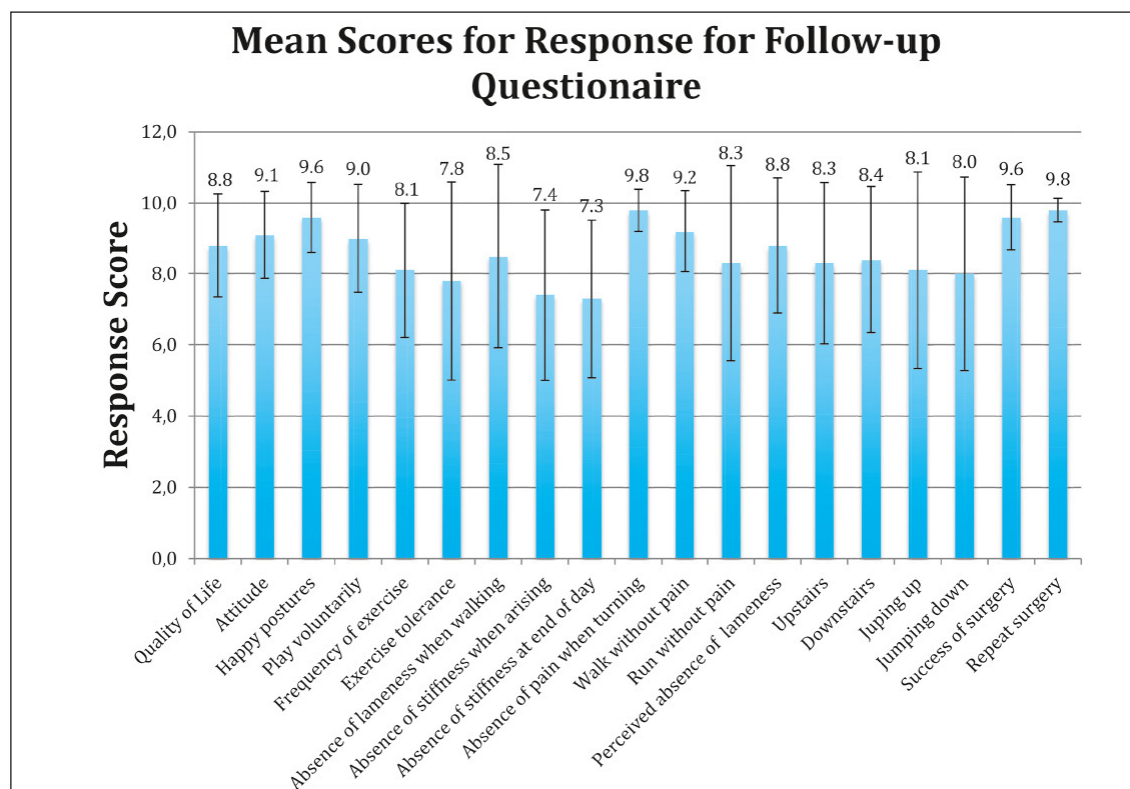
Of the 55 dogs included in the study, 11 underwent staged, bilateral corrective osteotomy for a total of 66 affected limbs undergoing surgery (► Appendix Table 1: available online at [www.vcot-online.com](http://www.vcot-online.com)). The mean time between staged, bilateral surgeries in these cases was  $37.1 \pm 25.3$  weeks (range: 9.7 – 77.3 weeks). The mean pre- and postoperative aLDFA was  $107.6^\circ \pm 5.8^\circ$  and  $94.1^\circ \pm 4.2^\circ$ , respectively, with an average correction of  $13.5^\circ \pm 5.9^\circ$  (range:  $3^\circ$ – $42^\circ$ ). Severity of medial patellar luxation was grade II (16 limbs), grade III (33 limbs), grade IV (14 limbs), or not recorded preoperatively (3 patients).

Partial or complete rupture of the cranial cruciate ligament was identified in 26/66 affected limbs, and managed by TPLO ( $n = 19$ ), tibial tuberosity advancement ( $n = 2$ ), and lateral fabellotibial suture ( $n = 5$ ). Two of the cases had cranial cruciate ligament tears previously diagnosed and treated (both with TPLO stabilization). Tibial deformity was identified in nine of the 66 limbs and included tibial valgus ( $n = 6$ ), tibial torsion ( $n = 3$ ), and excessive tibial plateau angle based on determination of the safe point ( $n = 1$ ) (19). Valgus and torsion were corrected in six limbs with a single tibial osteotomy (correction of tibial torsion), wedge osteotomy (correction of tibial valgus), or included with surgical stabilization of the stifle if indicated (TPLO with tibial wedge osteotomy).

Ancillary procedures were performed at the discretion of the surgeon. Tibial tuberosity transposition ( $n = 32$ ) and treatment of the trochlear sulcus (trochlear wedge recession, trochlear block recession, or abrasion trochleoplasty) ( $n = 38$ ) were performed as indicated. Lateral imbrication and medial release were reported as being performed in 29 and 16 limbs, respectively.



**Figure 2** A) Three-dimensional volumetric reconstruction of the femur with the CORA identified (white circle, CORA magnitude =  $12^\circ$ ) using the breed specific aLDFA of  $97^\circ$  degrees for this Labrador Retriever. B) Postoperative craniocaudal and C) mediolateral radiographic views; B) the postoperative aLDFA is  $96^\circ$  degrees, C) cortico-cancellous bone graft is visible caudal to the femur at the level of the osteotomy. Eight-week postoperative D) craniocaudal and E) mediolateral radiographic views demonstrating osteotomy healing (excellent union, >75% healing) and stable implants; note the incorporation of the cortico-cancellous bone graft previously seen in (C) into the callus caudal to the femur (E).



**Figure 3**  
Mean response scores for long-term follow-up questionnaire; the questionnaire can be found in the online Supplementary Material ([www.vcot-online.com](http://www.vcot-online.com)). Higher scores indicate better function/outcome.

A lateral fabella-patellar suture was performed in two limbs.

A variety of implants were used to stabilize the femur after osteotomy, including: LC-DCP<sup>a</sup> (n = 38), LCP<sup>a</sup> (n = 7), TPLO plate<sup>b</sup> (n = 3), ALPS<sup>c</sup> (n = 2), tibial head buttress plate<sup>a</sup> (n = 2), reconstruction plate<sup>a</sup> (n = 2), and T-plate<sup>a</sup> (n = 1).

Radiographic follow-up until osteotomy healing was available on 51/66 limbs (► Figure 2 D and E). The mean healing time (healing score of 3/4 or 4/4) was 73 ± 37 days in this group (range: 37 to 211 days). At the time of hospital re-evaluation, none of these patients had recurrence of medial patella luxation. Complications of surgical correction of femoral varus deformity included infection (2/51), implant failure (1/51), and persistent lameness postoperatively (1/51). Implants were removed in the two limbs with postoperative infection and treated with antibiotic medications based on the intra-operative cul-

tures and sensitivity. The implant failure occurred in a 66 kg English Mastiff at ~6 weeks postoperatively, at which time the dog became lame. Radiographs revealed two broken 3.5 cortical screws at the distal aspect of the nine-hole 3.5 broad LCP, and cut out of a locking screw. These implants were removed and replaced with a longer LCP<sup>a</sup>, and an additional ALPS<sup>c</sup> plate was applied on the craniomedial aspect of the femur. In the dog with the persistent lameness, the distal end of the bone plate was positioned quite cranial on the lateral trochlear ridge, and implant interference with the parapatellar fibrocartilage was suspected. The implants were removed 10 weeks postoperatively after bone healing was observed, and the lameness resolved. There was no evidence of infection based on the results of bacterial culture. No further problems were reported.

Long-term follow-up by telephone questionnaire was obtained for 29 limbs (26 dogs) at a mean of 74 ± 33 months postoperatively (range: 19–143 months). No additional procedures or complications were reported for any limb. In all cases for which long-term follow-up was obtained,

the owners were satisfied with the surgical outcome based on the results of the questionnaire. Results from this questionnaire are summarized in ► Figure 3; the highest scores were on questions relating to success of surgery (9.6/10) and whether this operation would be performed again (9.8/10), and the lowest scores related to stiffness when rising (7.4/10) and at the end of the day (7.3/10).

## Discussion

The findings of our study establishes the lateral closing wedge DFO as a successful and repeatable component of the comprehensive management of dogs with medial patella luxation associated with distal femoral varus, resulting in accurate reduction of the aL DFA, reliable bone union, and excellent client satisfaction. Additionally, the patellar relaxation rate in the group of patients with follow-up was zero, highlighting the likelihood that excessive femoral varus is a significant factor in the pathophysiology of medial patellar luxation in this cohort of dogs.

a DePuy Synthes® Vet, West Chester, PA, USA

b Slocum Enterprises, Eugene, OR, USA

c KYON Veterinary Surgical Products, Boston, MA, USA

A small degree of varus (between 4° and 8°) is present in most canine femora, and this parameter appears to vary both within and between breeds (18). In cases where femoral varus is implicated as contributing to medial patella luxation, the magnitude of femoral varus requiring surgical correction has not been clearly defined. It has been recommended to correct a varus deformity if it is greater than 10° to 12° (corresponding to aLDFA of >100°–102° in Labrador Retrievers); although, it should be noted that at the time this recommendation was made, the varus angle was compared to 90° (16). Failure to correct excessive femoral varus has been proposed as a reason for recurrence of patellar luxation in large-breed dogs (13, 16, 17). Postoperative femoral varus, as measured by the aLDFA, was consistently within the normal reference ranges previously reported, thus demonstrating that the lateral closing wedge DFO is an accurate method to correct distal femoral varus (18). Due to the complex three-dimensional shape of the femur, well-positioned radiographic views or three-dimensional reconstruction of CT images are required for accurate determination of femoral varus (17, 19).

While it is impossible to explain the individualized decision making of the many surgeons at the various institutions who contributed cases to this report, the group of surgeons involved had worked or trained together for several years and therefore have a similar approach to the decision making process. Prior to 2007, patients with aLDFA of 100° or more were corrected with a target aLDFA of approximately 90°. After 2007, patients with a preoperative aLDFA 8° to 10° greater than the reported breed specific normal value (or value of the normal opposite limb if present) were corrected to the breed specific normal angle, or a target angle of approximately 94° if no breed specific value was available. The femoral torsion angle was measured preoperatively, assessed intraoperatively, or both and then corrections were performed based on the discretion of the attending surgeon. Torsion correction was performed to increase the femoral torsion angle, with a target value of approximately 27°. Patellar tracking was evaluated intra-operatively to confirm that an appro-

appropriate torsion correction was performed. The decision to perform a distal femoral osteotomy in addition to other treatments, or to perform traditional treatments such as trochlear wedge or block recession and tibial tuberosity transposition alone was made for each individual patient. For instance, a Labrador Retriever with a preoperative aLDFA of 100° and femoral torsion angle of 27° that has a shallow trochlear groove and medial displacement of the tibial tuberosity may successfully be treated by traditional treatments such as trochlear wedge or block recession and tibial tuberosity transposition alone. However, another Labrador Retriever with a preoperative aLDFA of 100° and femoral torsion angle of 10° that has a normal trochlear groove and normal patellar ligament to tibial tuberosity alignment is best treated by distal femoral corrective osteotomy in the authors' opinion. In the latter case, deepening of the trochlear groove or tibial tuberosity transposition is not necessary since trochlear depth and patellar ligament alignment are already normal. Distal femoral osteotomy with angular and torsional correction of the femur will resolve the skeletal mal-alignment in the latter case; thus two Labrador Retrievers with similar aLDFA measurements might be treated differently. For this reason, a singular cut-off value for aLDFA necessitating distal femoral osteotomy cannot be advocated. Instead, we recommend case by case evaluation to identify all the abnormalities present, and development of a comprehensive surgical plan that addresses each of the abnormalities, consistent with the current literature (19).

In this cohort of dogs, DFO was employed as part of the surgical management plan for femoral varus and medial patellar luxation. Additionally, some had correction of tibial angular or torsional deformity and cranial cruciate ligament pathology. It has been speculated that increased internal rotation of the stifle caused by medial patellar luxation may contribute to cranial cruciate ligament pathology (3, 8). In addition, cranial cruciate ligament disease and subsequent rupture may exacerbate pre-existing low grade medial patellar luxation due to increased internal rotation of the tibia at the stifle joint (6, 8). Our findings demon-

strate that femoral varus is an important component of medial patellar luxation in some dogs. The need for stifle stabilization and possible correction of tibial deformity should be anticipated in the preoperative planning.

A previous report has shown healing of distal femoral osteotomies to be consistently reliable (16). Mean time to radiographic healing was 73 days (10.4 weeks) in this study, which is longer than others previously reported (16). However, the time intervals to radiographic follow-up after surgery were inconsistent, making comparison of healing at specific postoperative times difficult. The actual mean healing time is likely to have been shorter based on the inconsistency of re-examination timing. We did not directly compare our method of angular and torsional correction to other methods of DFO, such as an opening wedge correction. However, we believe that the method described here is superior based upon the accuracy and stability achieved. An opening wedge osteotomy might be performed with similar accuracy with limb realignment; however, it would not have the same degree of stability due to lack of bone apposition. The latter would probably affect the healing rate, which we can reasonably assume might be longer.

In this study, there were four cases with major complications requiring additional surgery. An infection rate of 3.9% is not unexpected as this is similar to that reported for other major orthopaedic surgical procedures, and was resolved with implant removal and appropriate antibiotic therapy. The large size of one patient may have led to excessive stress on the single bone plate and screws resulting in implant failure. Based on this experience, we suggest that additional implants (such as a craniomedial bone plate in addition to the lateral plate) may be indicated for active, giant breed dogs. Persistent lameness in one case resolved after the plate was removed. These four complications were successfully addressed, but did require additional surgery. This complication rate compares favourably with a recent retrospective study on surgical correction of grade 4 medial patellar luxation, in which performing a corrective osteotomy was the only variable associated with major compli-

ation occurrence (24). Nonetheless, as stated by the authors of that study, the sample size of corrective osteotomies was small, and only two of the four with major complications were directly related to the osteotomy.

Our results obtained by telephone questionnaire indicate that correction of medial patella luxation by DFO can lead to long-term patient comfort with good functional outcome. Previous studies have used clinical examination, client questionnaires, and owner assessments to evaluate postoperative lameness and limb function (21, 23). Although no questionnaires were completed prior to surgery to use as a comparison, all owners who responded considered the surgery a success and would have the procedure performed again under the same circumstances. The lowest scores relating to stiffness when arising may be reflective of development of osteoarthritis in the stifle, hip, or other joints.

Recurrence of patellar luxation was not detected in any of the limbs (51/66) that were evaluated in the short-term after surgery (ranging from 5 to 22 weeks postoperatively). This is consistent with the outcome in another study evaluating medial patellar luxation treated by distal femoral osteotomy (16). In contrast, previous reports indicate that patellar re-luxation occurs in eight to 48% of affected patients in which femoral varus was neither measured nor addressed (2, 6, 10).

Limitations of this study reflect its retrospective design, in which the accuracy of the data relies on the accuracy of the medical entries. Additionally, there was no standardization or set protocol for lameness evaluation, preoperative planning, or surgical technique. Corrective surgical procedures were tailored based on the abnormalities identified in each case, as deemed appropriate by the attending surgeon. During the period of this study, the preoperative planning and surgical technique were refined based on our growing experience. It is likely that not all procedures were recorded in all patients, as medial release and lateral imbrication would generally be indicated in most dogs with medial patellar luxation. Likewise, time intervals of clinical and radiographic follow-up were not standardized, hindering our ability to accu-

rately determine the time to radiographic union. Due to the nature of the study, a control group was not used and thus we were unable to directly compare patients that had a DFO to those that were treated only with alternative corrective procedures, such as trochleoplasty and tibial tuberosity transposition. This study also was limited by the short in-hospital follow-up period. Continued clinical and radiographic follow-up would allow us to more thoroughly assess long-term outcome and note complications that arise later, such as diminished clinical function, and radiographic progression of osteoarthritis.

A better understanding of the normal and pathological values of both femoral varus and torsion in clinical patients is needed to more precisely determine when surgical correction is warranted. In addition to determining breed specific joint angles, a better understanding of the underlying cause of medial patellar luxation in large breed dogs will continue to allow a more refined approach to its prevention and treatment. In both the research and clinical settings, additional data on coxa vara, femoral anteversion angles, femoral varus angles, tibial deformities, and quadriceps alignment in dogs with medial patellar luxation will aid in reaching this objective. Future studies are needed to determine additional breed specific aLDFA in both clinically normal dogs, and those with medial patellar luxation, with an ultimate goal of identifying the threshold at which femoral varus should be surgically corrected, while considering co-morbidities.

### Conflict of interest

The authors declare no conflict of interest or funding for this manuscript.

### References

- Ruble RP, Hird DW. Congenital abnormalities in immature dogs from a pet store: 253 cases (1987–1988). *J Am Vet Med Assoc* 1993; 202: 633–636.
- Gibbons SE, Macias C, Tonzing MA, et al. Patellar luxation in 70 large breed dogs. *J Small Anim Pract* 2006; 47: 3–9.
- Hayes AG, Boudrieau RJ, Hungerford LL. Frequency and distribution of medial and lateral patellar luxation in dogs – 124 cases (1982–1992). *J Am Vet Med Assoc* 1994; 205: 716–720.

- Johnson AL, Broaddus KD, Hauptman JG, et al. Vertical patellar position in large-breed dogs with clinically normal stifles and large-breed dogs with medial patellar luxation. *Vet Surg* 2006; 35: 78–81.
- Remedios AM, Basher AWP, Runyon CL, et al. Medial patellar luxation in 16 large dogs – a retrospective study. *Vet Surg* 1992; 21: 5–9.
- Arthurs GI, Langley-Hobbs SJ. Complications associated with corrective surgery for patellar luxation in 109 dogs. *Vet Surg* 2006; 35: 559–566.
- Bound N, Zakai D, Butterworth SJ, et al. The prevalence of canine patellar luxation in three centres: clinical features and radiographic evidence of limb deviation. *Vet Comp Orthop Traumatol* 2009; 22: 32–37.
- Piermattei DL, Flo GL, Decamp CE. Patellar luxation. In: Piermattei DL, Flo GL, Decamp CE, editors. *Handbook of Small Animal Orthopedics and Fracture Repair*. 4<sup>th</sup> ed. St. Louis: Saunders; 2006. pg. 562–582.
- Hulse DA. Pathophysiology and management of medial patellar luxation in the dog. *Vet Med Small Anim Clin* 1981; 76: 43–51.
- Willauer CC, Vasseur PB. Clinical results of surgical correction of medial luxation of the patella in dogs. *Vet Surg* 1987; 16: 31–36.
- Slocum B, Slocum TD. Patellar luxation algorithm. In: Bojrab M, editor. *Current Techniques in Small Animal Surgery*. 4<sup>th</sup> ed. Baltimore: Williams & Wilkins; 1998. pg. 1222–1231.
- Dudley RM, Kowaleski MP, Drost WT, et al. Radiographic and computed tomographic determination of femoral varus and torsion in the dog. *Vet Radiol Ultrasound* 2006; 47: 546–552.
- Peruski AM, Kowaleski MP, Pozzi A. Treatment of medial patellar luxation and distal femoral varus by femoral wedge osteotomy in dogs: 30 Cases (2000–2005). *Proceedings of the 2<sup>nd</sup> World Veterinary Orthopaedic Congress*; 2006 February 25–March 4; Keystone, CO, USA. pg 240.
- Roch SP, Gemmill TJ. Treatment of medial patellar luxation by femoral closing wedge osteotomy using a distal femoral plate in four dogs. *J Small Anim Pract* 2008; 49: 152–158.
- Kaiser S, Cornely D, Golder W, et al. The correlation of canine patellar luxation and the anteversion angle as measured using magnetic resonance images. *Vet Radiol Ultrasound* 2001; 42: 113–118.
- Swiderski JK, Palmer RH. Long-term outcome of distal femoral osteotomy for treatment of combined distal femoral varus and medial patellar luxation: 12 cases (1999–2004). *J Am Vet Med Assoc* 2007; 231: 1070–1075.
- Kowaleski MP. Femoral corrective osteotomy for medial patellar luxation. *Proceedings of the American College of Veterinary Surgery Symposium*; 2006 October 5–7; Washington, DC, USA. pg. 473–476.
- Tomlinson J, Fox D, Cook JL, et al. Measurement of femoral angles in four dog breeds. *Vet Surg* 2007; 36: 593–598.
- Kowaleski MP, Boudrieau RJ, Pozzi A. The stifle joint. In: Tobias KM, Johnson SA, editors. *Veterinary Surgery – Small Animal*. St. Louis, MO: Elsevier Saunders; 2012. pg. 906–998.
- Langenbach A, Marcellin-Little DJ. Management of concurrent patellar luxation and cranial cruciate ligament rupture using modified tibial plateau leveling. *J Small Anim Pract* 2010; 51: 97–103.

21. Weh JL, Kowaleski MP, Boudrieau RJ. Combination tibial plateau levelling osteotomy and transverse corrective osteotomy of the proximal tibia for the treatment of complex tibial deformities in 12 dogs. *Vet Surg* 2011; 40: 670–686.
22. Glaser D, Langlais F. The ISOLS radiological implants evaluation system. In: Langlais F, Tomeno B editors. *Limb Salvage: Major Reconstructons in Oncologic and Nontumoral Conditions*. Berlin, Germany: Springer; 1991. pg xxiii-xxxi.
23. Innes JF, Bacon D, Lynch C, et al. Long-term outcome of surgery for dogs with cranial cruciate ligament deficiency. *Vet Rec* 2000; 147: 325–328.
24. Hans EC, Kerwin SC, Elliott AC, et al. Outcome following surgical correction of grade 4 medial patellar luxation in dogs: 47 stifles (2001–2012). *J Am Anim Hosp Assoc* 2016; 52: 162–169.

